

## How to Approach a Patient with a Zenker's Diverticulum

Mihir S. Wagh<sup>1</sup> and Peter V. Draganov<sup>2</sup>

<sup>1</sup>Division of Gastroenterology, University of Colorado-Denver, Aurora, Colorado; and Division of <sup>2</sup>Gastroenterology and Hepatology, University of Florida, Gainesville, Florida



**Z**enker's diverticulum (ZD) is a hypopharyngeal outpouching in an area of weakness called Killian's triangle. Symptomatic ZD are associated with dysphagia and regurgitation. Treatment involves myotomy of the cricopharyngeus

muscle and septotomy between the ZD and esophagus. Traditionally, surgical management has been the mainstay of treatment, but flexible endoscopic septotomy (FES) has now become accepted as a viable minimally invasive treatment option.<sup>1</sup> Open surgical methods, including transcervical myotomy with diverticulectomy or diverticulopexy, are now reserved for ZD not amenable to peroral management. Transoral stapling performed with a rigid esophagoscope by otolaryngologists remains a treatment option, but requires general anesthesia and an extreme neck extension, making it not suitable for elderly patients with limited neck mobility, who are often the majority of patients with ZD. Furthermore, the bulky rigid device can be difficult to maneuver and treat small ZD owing to poor visualization and difficulty in isolating the septum. Importantly, the rigid staple design does not cut/staple all the way to the end of the blades resulting in a residual pouch, which seems to be the main reason for the relatively high recurrence rate of 20%–30%.<sup>2</sup> As a result, FES has become first line therapy<sup>1</sup> at most tertiary centers.

FES seems to offer cost savings owing to shorter procedure time, shorter length of stay, and earlier resumption of diet<sup>3</sup> combined with similar efficacy and adverse event (AE) rates compared with rigid stapling.<sup>4</sup> Furthermore, FES is usually performed in the endoscopy unit rather than in the operating room, often with moderate sedation. Most importantly despite the lack of prospective head-to-head studies comparing rigid stapling versus flexible endoscopic treatment, there are numerous publications highlighting high efficacy and safety of FES.<sup>5,6</sup> A recent meta-analysis showed that FES was effective and safe with a pooled success of 91%, AE rate of 11.3%, and recurrence rate of 11%.<sup>7</sup> Another

recent multicenter study on FES for ZD reported that overall technical and clinical success was 98.1% and 78.1%, respectively, with 8.1% AE.<sup>8</sup>

The focus of this article, therefore, is to understand the approach to management of ZD with an emphasis on FES.

### How Is ZD Diagnosed and What Is the Workup Needed?

Most patients with symptoms of dysphagia and regurgitation are evaluated with an upper endoscopy and/or barium esophagram (or speech and swallow study), which shows the characteristic hypopharyngeal diverticulum at the level of the cricopharyngeus. It should be emphasized that special attention should be paid during esophageal intubation while performing upper endoscopy in patients with dysphagia, because a small ZD can be easily missed when the endoscope is advanced quickly into the esophagus. More importantly, blind esophageal intubation can lead to inadvertent passage of the endoscope into the ZD and perforation. The esophagus and gastroesophageal junction should be examined carefully to rule out other causes of dysphagia.

### Which Technique Is Preferred for FES for ZD?

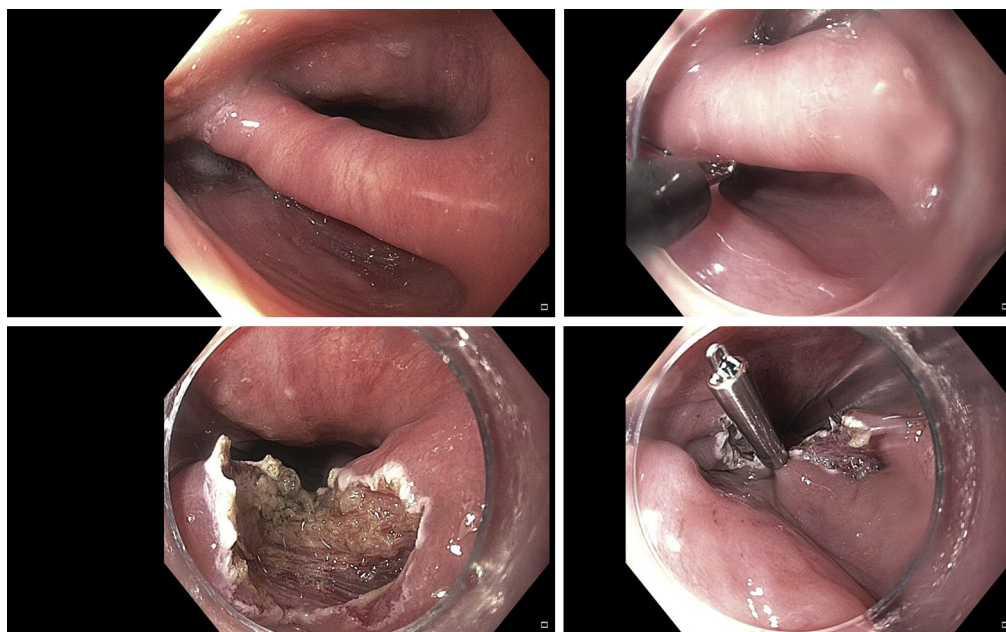
Various techniques and devices have been used for FES for ZD. In the initial description a needle knife was used,<sup>9,10</sup> but more recently multiple endoscopic submucosal dissection knives have been used successfully. With any of these knives, the basic steps of the procedure include endoscopic visualization of the septum and cricopharyngeus myotomy with septotomy to create an overflow from the ZD to the esophagus, allowing easy passage of food into the esophageal lumen, thereby relieving symptoms of dysphagia and regurgitation. To achieve this, various flexible endoscopic approaches have been described:

Most current article

© 2021 by the AGA Institute  
0016-5085/\$36.00

<https://doi.org/10.1053/j.gastro.2020.11.018>

**Figure 1.** Traditional flexible endoscopic septotomy for Zenker's diverticulum. *Top left*, Septum between the Zenker's diverticulum and esophageal lumen. A Hook knife septotomy is shown in the *top right* and *bottom left*. *Bottom right*, An endoscopic clip placed at the base of the septotomy incision. (Photos courtesy of Dr. Mihir S. Wagh.)



- Traditional endoscopic septotomy utilizing the original technique described above with a needle-type knife (Figure 1).
- Double-incision endoscopic “myectomy” of the septum, consisting of parallel excisions on the septum followed by wedge-shaped snare resection at the resection base.<sup>11</sup> In this report, 64 patients underwent FES for ZD, and 10 of 44 patients (22.7%) had recurrence of ZD in the traditional myotomy/septotomy cohort, whereas no recurrence was documented in the myectomy cohort (0/20 patients;  $P = .02$ ) at a median follow-up of 19.1 months. There was no statistical difference in improvement of dysphagia (86.4% and 90.0% in the myotomy and myectomy cohorts, respectively;  $P = .99$ ) or in AE (11.4% vs 10%).
- Most recently, submucosal tunneling endoscopic septum division (ST-endoscopic submucosal dissection or Z-POEM) has been gaining increasing interest for treatment of ZD (Figure 2) using principles of per-oral endoscopic myotomy (POEM).<sup>12-14</sup> In this technique, mucosal incision and submucosal tunneling is performed starting 1–2 cm proximal to the septum, and the tunnel is extended caudally on either side of the septum, followed by endoscopic septotomy. In their multicenter retrospective study on Z-POEM, Yang et al<sup>14</sup> reported overall technical success in 73 of 75 patients (97.3%) and clinical success in 69 of 75 (92%). AE occurred in 6.7%. A modification of this approach is to perform the mucosal incision on the septum (rather than proximal to it) and tunnel on either side to isolate the septum, followed by septotomy.<sup>15,16</sup>

These techniques for FES have evolved together with the advancement in endoscopic resection methods and with the

availability of newer endoscopic accessories, but there are limited data directly comparing these different approaches. However, all these techniques seem to be able to sever the septum between the esophagus and ZD, providing symptom relief with a low rate of AE.

## Which Devices Should Be Used for FES for ZD?

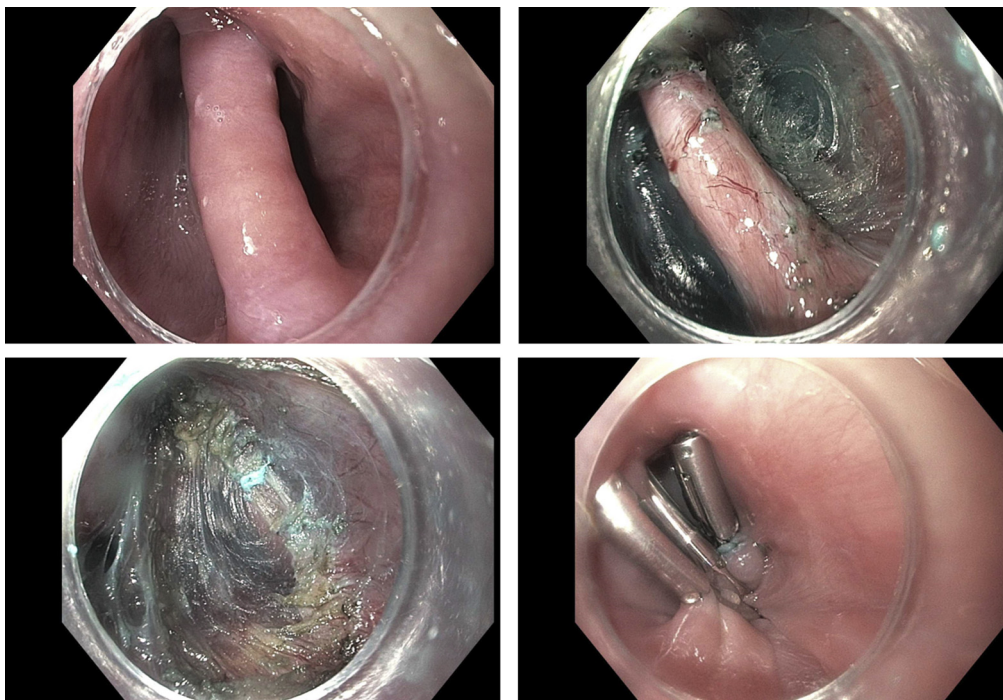
A wide variety of endoscopic knives (outlined in Table 1), mainly borrowed from the endoscopic submucosal dissection armamentarium have been used,<sup>5,6</sup> purely based on endoscopist preference without robust data supporting the use of one device over another. Our group assessed practice patterns for septotomy for ZD and found that the Hook knife and needle knife were most commonly used. Clinical success was higher with the Hook knife (96.67%), compared with needle knife (76.6%) and insulated tip knife (47.1%).<sup>8</sup> Unfortunately, recommendations on the preferred type of device are not possible owing to the lack of high-quality comparative data.

Multiple accessories have been used to improve visualization and facilitate septotomy (Table 1). Although 1 study has shown improved outcomes using a special diverticuloscope,<sup>17</sup> there was no association between device, technique, and AE in other studies.<sup>7</sup> We have also found similar results where use of accessories such as an orogastric tube, distal attachment cap, modified overtube, endoscopic clips, or intraprocedure or postprocedure antibiotics did not significantly affect outcomes.<sup>8</sup>

## Which Zenker's Diverticula Are Suitable for FES?

ZD of all sizes have been successfully treated with FES, with only the relatively uncommon giant

# MENTORING, EDUCATION, AND TRAINING CORNER



**Figure 2.** Z-POEM technique for flexible endoscopic septotomy for Zenker's diverticulum. Endoscopic view of the septum between the Zenker's diverticulum (left of septum) and esophageal lumen (right of septum) is shown on the *top left*. The exposed muscular septum is clearly seen in the submucosal tunnel (*top right*). Complete septotomy to the level of the base of the Zenker's diverticulum is shown in the *bottom left*. Closure of the mucosal incision with endoscopic clips is shown in the *bottom right*. (Photos courtesy of Dr. Mihir S. Wagh.)

diverticula being treated surgically. Costamagna et al<sup>18</sup> have suggested a best success rate (100% at 6 months and 71% at 48 months) for ZD 30–49 mm in size with septotomy >25 mm.<sup>18</sup> However, it should be noted that in this study a limited needle-knife septotomy was performed of the proximal septum only, regardless of the length of the remaining septum. Today, most endoscopists strive for complete septotomy to the base of the septum, hence these results may not be applicable universally. With the availability of newer endoscopic knives allowing precise dissection, injection, and hemostasis, FES has become accepted for all ZD as the preferred treatment option.

## Are There Any Advantages with the Submucosal Dissection Methods Such as Z-POEM?

The main question is “are newer submucosal dissection techniques worth the extra effort?” Traditional FES is highly effective and performed in <30 minutes, although it is criticized for often leaving behind a small residual septum that may cause recurrent dysphagia. However, this recurrence many months or years later may not be clinically relevant in elderly patients in whom ZD typically occurs and, if symptomatic, can be easily tackled with a repeat endoscopy for incision of the residual septum when the esophageal and diverticular walls

**Table 1.** Devices for FES for Zenker's Diverticulum

| Type                | Name  | Comments   |
|---------------------|---|--|
| Accessories         | Diverticuloscope (or modified overtube)         | Not available in the United States   |
|                     | Distal attachment cap                           | Exposure of the septum and increased endoscope stability                           |
|                     | Orogastric or nasogastric tube                  | Identification of esophageal lumen and protection of contralateral esophageal wall |
|                     | Endoscopic clips                                | Approximate edges of the septotomy incision  |
| Endoscopic knives   |   | For septotomy/myotomy  |
| Needle-type knives  | Needle-knife <sup>a</sup>                       |  |
|                     | Hook knife <sup>b</sup>                         |  |
|                     | Insulated tip knife (IT/IT2 knife) <sup>b</sup> |  |
| Scissor-type knives | SB knife <sup>b</sup>                           |  |
|                     | ClutchCutter <sup>c</sup>                       |  |

<sup>a</sup>Needle-knife (Boston Scientific, Marlborough, MA).

<sup>b</sup>Hook knife, Insulated Tip knife, SB knife (Olympus America, Center Valley, PA).

<sup>c</sup>ClutchCutter (Fujifilm, Fujifilm Medical Systems USA, Wayne, NJ).

**Table 2.** Unresolved Issues for Flexible Endoscopic Treatment of ZD

|   |
|---|
| Which are the preferred devices for FES for ZD?   |
| Do any one of the described techniques provide any specific advantages over the other?  |
| Is there any clinical situation which will favor a particular technique for FES?  |
| During traditional septotomy is it acceptable to leave a small bridge of tissue at the bottom of the septotomy to hopefully prevent perforation yet not compromise clinical improvement or increase recurrence? |
| If the tunneling technique is selected, is direct tunneling on the septum (shorter tunnel) or starting the tunnel proximal to the septum (longer tunnel), the preferred approach?                               |
| Is it necessary to place an orogastric tube to facilitate FES?  |
| Should the traditional septotomy be routinely closed with clips?  |
| Is routine postprocedure radiologic imaging (esophagram) needed to document lack of extravasation, thereby obviating need for hospital admission?   |
| Are periprocedural antibiotics needed?  |

FES, flexible endoscopic septotomy; ZD, Zenker's Diverticulum.

have adhered, thereby decreasing risk of perforation. In addition, we have shown that there was no significant difference in technical and clinical success between traditional septotomy and submucosal dissection for treatment of ZD (97% vs 95.8% [ $P = .559$ ] and 75.2% vs 90.9% [ $P = .155$ ], respectively),<sup>8</sup> but this was before Z-POEM was incorporated in our practices. "Third space endoscopists," however, counter this by stating that Z-POEM techniques allow a limitless depth of septotomy to the base of (and even beyond) the septum underneath the "protective net" of the mucosal layer with an acceptable AE rate.<sup>12-14</sup> Whether this theoretical advantage translates to clinical benefit by decreasing the recurrence of symptoms, remains to be answered. Z-POEM can therefore be used for all sizes of ZD, including small ZD of <3 cm,<sup>16</sup> where a traditional septotomy on the short septum would not completely divide the sphincter muscle, and also for large ZD. Also, owing to increased experience with POEM for achalasia, and with the minor modification of the Z-POEM technique to start the incision and tunnel on the septum rather than proximal to it, it is our personal experience (Wagh MS) and that of other third space endoscopists that Z-POEM procedure times have become significantly shorter as well (around 30 minutes).<sup>16,19</sup> Future studies comparing Z-POEM with traditional FES will hopefully clarify these potential advantages and answer this burgeoning question.

## Is Routine Clipping of the Base of the Septotomy Incision Necessary?

One of the most dreaded AE of FES is perforation with leakage into the soft tissues of the neck and mediastinum. This complication is attributed to extension of the incision too far distally in an effort to completely incise the septum. Therefore, some endoscopists routinely approximate the edges of the septotomy incision with clips. In a recent study,<sup>8</sup> there was no difference in AE with or without routine placement of endoscopic clips after septotomy, but no studies have directly compared the 2 approaches and this question remains to be answered.

## Summary of Unresolved Controversies

It is clear that FES is a safe and highly effective technique for therapy of ZD. Nevertheless, the technique is still not standardized and there are wide variations in practice patterns, and devices used based on endoscopist experience, preference, and available accessories. Hence, multiple questions remain open for discussion (Table 2).

It is also imperative to better define the learning curve and training process for FES and assess the impact of endoscopist background in third space endoscopy on acquiring skills for FES. Because symptomatic ZD is a relatively uncommon condition, for now it seems reasonable to concentrate FES at the major tertiary referral centers with expertise in interventional endoscopy and preferably in third space endoscopy. Furthermore, adequate support from interventional radiology and surgical services is of paramount importance to handle the rare but potentially life-threatening AE such as perforation.

## Conclusions

FES is an effective therapy for ZD with a low rate of AE. It is less invasive than open surgery, avoids many of the limitations of rigid peroral stapling, and should be considered a first-line therapy for symptomatic ZD. A variety of newer devices and emerging techniques such as Z-POEM may further increase the efficacy and safety of the procedure. Owing to the rarity of the condition, studies on ZD have included heterogeneous patient populations, and been restricted to retrospective reports or small prospective series. Robust randomized trials with standardized definitions of outcomes are lacking. Future studies comparing these approaches with long-term follow-up are needed. Until then, in expert hands, all flexible endoscopic modalities seem to deliver high clinical success, low AE rate and potential cost savings.

## References

1. Law R, Katzka DA, Baron TH. Zenker's diverticulum. *Clin Gastroenterol Hepatol* 2014;12:1773–1782.
2. Bonavina L, Aiolfi A, Scolari F, et al. Long-term outcome and quality of life after transoral stapling for Zenker diverticulum. *World J Gastroenterol* 2015;21:1167–1172.
3. Albers DV, Kondo A, Bernardo WM, et al. Endoscopic versus surgical approach in the treatment of Zenker's diverticulum: systematic review and meta-analysis. *Endosc Int Open* 2016;4:E678–E686.
4. Repici A, Pagano N, Fumagalli U, et al. Transoral treatment of Zenker diverticulum: flexible endoscopy versus endoscopic stapling. A retrospective comparison of outcomes. *Dis Esophagus* 2011;24:235–239.
5. Perbtani Y, Suarez A, Wagh MS. Techniques and efficacy of flexible endoscopic therapy of Zenker's diverticulum. *World J Gastrointest Endosc* 2015;7:206–212.
6. Ishaq S, Sultan H, Siau K, et al. New and emerging techniques for endoscopic treatment of Zenker's diverticulum: state-of-the-art review. *Dig Endosc* 2018;30:449–460.
7. Ishaq S, Hassan C, Antonello A, et al. Flexible endoscopic treatment for Zenker's diverticulum: a systematic review and meta-analysis. *Gastrointest Endosc* 2016; 83:1076–1089.
8. Mittal C, Diehl DL, Draganov PV, et al. Practice patterns, techniques, and outcomes of flexible endoscopic myotomy for Zenker's diverticulum: retrospective multi-center study. *Endoscopy* 2020 Jul 14. <https://doi.org/10.1055/a-1219-4516>. [Epub ahead of print].
9. Mulder CJ, den Hartog G, Robijn RJ, et al. Flexible endoscopic treatment of Zenker's diverticulum: a new approach. *Endoscopy* 1995;27:438–442.
10. Ishioka S, Sakai P, Maluf Filho F, et al. Endoscopic incision of Zenker's diverticula. *Endoscopy* 1995; 27:433–437.
11. Pang M, Koop A, Brahmabhatt B, et al. Comparison of flexible endoscopic cricopharyngeal myectomy and myotomy approaches for Zenker diverticulum repair. *Gastrointest Endosc* 2019;89:880–886.
12. Li QL, Chen WF, Zhang XC, et al. Submucosal tunneling endoscopic septum division: a novel technique for treating Zenker's diverticulum. *Gastroenterology* 2016; 151:1071–1074.
13. Hernandez Mondragon OV, Solorzano Pineda MO, Blancas Valencia JM. Zenker's diverticulum: submucosal tunneling endoscopic septum division (Z-POEM). *Dig Endosc* 2018;30:124.
14. Yang J, Novak S, Ujiki M, et al. An international study on the use of peroral endoscopic myotomy in the management of Zenker's diverticulum. *Gastrointest Endosc* 2020;91:163–168.
15. Kedia P, Fukami N, Kumta NA, et al. A novel method to perform endoscopic myotomy for Zenker's diverticulum using submucosal dissection techniques. *Endoscopy* 2014;46:1119–1121.
16. Repici A, Spadaccini M, Belletrutti PJ, et al. Peroral endoscopic septotomy for short-septum Zenker's diverticulum. *Endoscopy* 2020;52:563–568.
17. Costamagna G, Iacopini F, Tringali A, et al. Flexible endoscopic Zenker's diverticulotomy: cap-assisted technique vs. diverticuloscope-assisted technique. *Endoscopy* 2007;39:146–152.
18. Costamagna G, Iacopini F, Bizzotto A, et al. Prognostic variables for the clinical success of flexible endoscopic septotomy of Zenker's diverticulum. *Gastrointest Endosc* 2016;83:765–773.
19. Khashab MA. Response to Ishaq et al. *Gastrointest Endosc* 2020;91:205–206.

---

## Correspondence

Address correspondence to: Mihir S. Wagh, MD, FACP, FASGE, Interventional Endoscopy, Division of Gastroenterology, University of Colorado-Denver, 1635 Aurora Court, F735, Aurora, CO 80045. e-mail: [mihir.wagh@cuanschutz.edu](mailto:mihir.wagh@cuanschutz.edu).

## Conflicts of interest

The authors have made the following disclosures: Mihir S. Wagh is a consultant for Boston Scientific, Olympus, and Medtronic. Peter V. Draganov is a consultant for Boston Scientific, Olympus, Cook, Microtech, Lumendi, Medtronic, Fuji Film, Merit, and Steris.